

# Emergency Orthopedics

*Kevin P. Kilgore, M.D., FACEP*

## Introduction

Many patients with musculoskeletal symptoms will initially present to the ED. Everyone involved in the care of these patients needs to be versed in the basics of orthopedics. This includes knowing which fractures not to send home (e.g. supracondylar humeral fractures in children), which fractures may not be apparent on radiographs (e.g. navicular, radial head fractures), and basic splinting techniques.

Many problems can be avoided if the following 9 general principles are kept in mind:

- History and physical examination will predict x-ray findings with a high degree of accuracy
- If x-ray films appear negative but a fracture is suspected clinically, treat for a fracture.
- Be familiar with proper x-ray views and do not accept inadequate studies.
- Perform x-ray examinations before reductions, unless a delay may prove injurious.
- Neurovascular competence should be checked and recorded before and after all reductions.
- Circumferential casting in plaster is usually not prudent for the emergency physician.
- The ability to ambulate safely before being discharged from the emergency department.
- Explicit after-care instructions should be provided before leaving the department, including instruction in monitoring signs of neurovascular compromise, splint care, and follow-up.
- In the multiple trauma patient, non-critical orthopedic injuries can be diagnosed and treated after airway, head, and intracavitary injuries are addressed.

All orthopedic injuries should be described precisely and according to established conventions. By using these conventions you will be able to convey in words an image of the "image" of what fracture exists to your consulting orthopedist.

## Fractures

**Nomenclature:** A fracture is defined as a break in the continuity of bone or cartilage. Clinical features of a fracture includes a loss of function, tenderness, swelling, abnormal mobility, and deformity. Radiographic studies are used to confirm your clinical suspicion. Special studies (special views, tomography, radionuclide bone scans, or computed tomography) should be undertaken when clinical suspicion conflicts with the findings on a routine radiograph.

**General Descriptors:** Description of a fracture should begin by stating whether the fracture is closed or open (other, less-desirable terms are simple or compound, respectively). In a closed fracture, the skin and soft tissue overlying the fracture site are intact. If the fracture is exposed to the outside environment in any manner, it is open. This exposure may be as obscure as a puncture wound or as gross as splintered bone protruding through the skin. Sometimes it is difficult to determine whether a small wound in proximity to a fracture actually communicates with that fracture. If doubt exists, assume that an open fracture is present.

Mandatory	Additional modifiers
1. Open vs. closed	1. Complete vs. incomplete
2. Exact anatomic location	2. Involvement of articular surface (%)
3. Direction of fracture line	3. Avulsion
4. Simple/comminuted	4. Impaction
5. Position (displacement, alignment)	a. Depression
	b. Compression
	5. Pathologic
	6. Stress

**Table 1 - Terms Used to Describe a Fracture**

Open fractures are considered true orthopedic emergencies because of the risk of infection, and therefore no time should be wasted in commencing therapy. Wounds should be cultured, covered with sterile dressings, and parenteral antibiotics instituted as early as possible. The classification and management of open fractures are depicted in the box above, right.

The next item to be noted in the description of a fracture is the exact anatomic location, including the name of the bone, left or right, and standard reference points, for example, the humeral neck or posterior tibial tubercle. Long bones can be divided into thirds—proximal, middle, or distal—and these thirds or the junction of any two of them (e.g., "the junction of the middle and distal third of the tibia . . .") may be used to describe fractures. The most descriptive language possible should be used. Thus it is better to say "closed fracture of the right ulnar styloid" rather than "closed fracture of the right distal ulna," since the former conveys more precise anatomic information.

### **Classification and Emergency Management of Open Fractures**

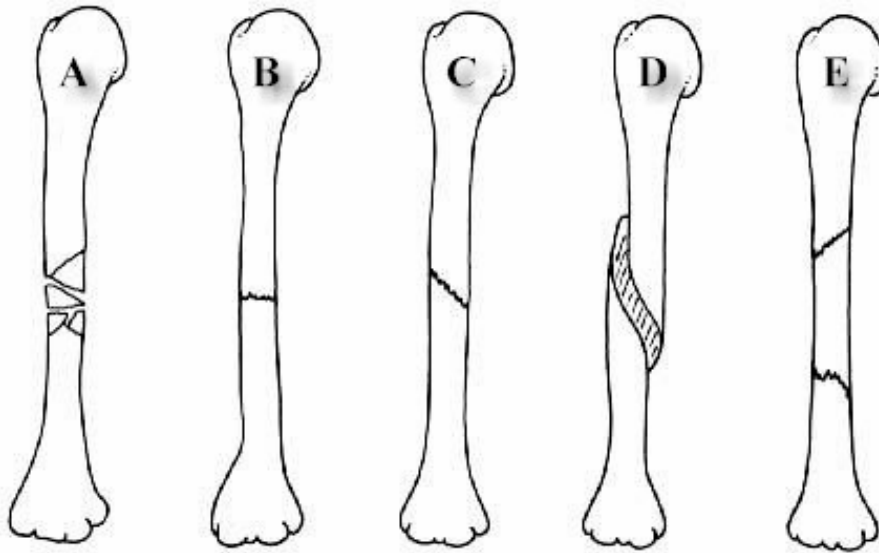
#### **Grades of Wounds**

Grade I	Wound less than 1 cm long, punctured from below
Grade II	Laceration up to 5 cm long; no contamination or crush, no excessive soft-tissue loss, flaps, or avulsion
Grade III	Large laceration, associated contamination or crush; frequently includes a segmental fracture

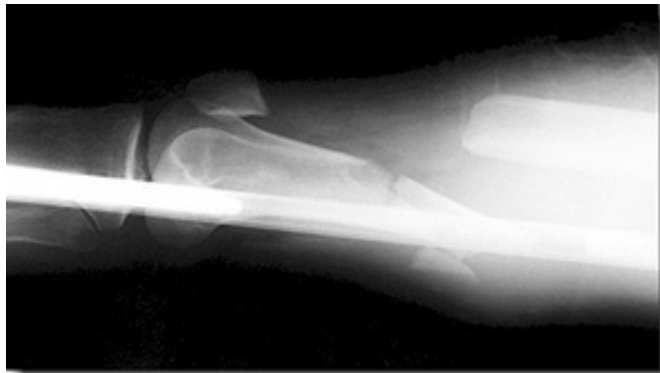- A Involves extensive soft-tissue stripping of bone
- B Periosteal stripping has occurred
- C Major vascular injury present

#### **Management**

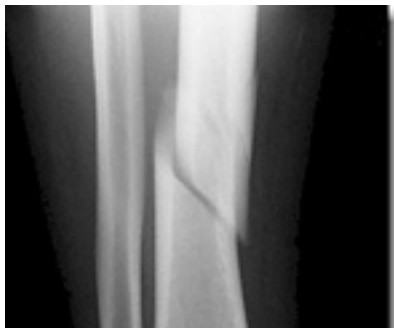1. Control hemorrhage in field with sterile pressure dressing after carefully removing gross debris (leaves, wood, etc.).
2. Splint without reduction, unless there is vascular compromise.
3. In emergency department obtain a culture, then irrigate with saline and cover with saline-soaked sponges.
4. Begin intravenous antibiotic, usually a cephalosporin.
5. Administer tetanus prophylaxis including tetanus immune globulin for large crush wounds.



Five additional modifiers can be used to describe the direction of the fracture line in relation to the long axis of the bone in question. (A) **transverse fracture** (B) occurs at a right angle to the long axis of the bone, whereas an **oblique fracture** (C) runs obliquely to the long axis. A **spiral fracture** (D) results from a rotational force and encircles the shaft of a long bone in a spiral fashion. A fracture in which there are more than two fragments present is termed **comminuted** (A). A **segmental fracture** (E) involves a "free-floating" central component with at least two fracture lines present.



**Alignment** refers to the relationship of the longitudinal axis of one fragment to another; deviation from the normal alignment is termed angulation. It is important to mention the direction of angulation if it exists. This is determined by the direction of the apex of an angle formed by the two fracture fragments. This angle will be opposite to the direction of displacement of the distal fragment. Thus this x-ray shows a comminuted fracture involving the distal one-third of the femur with dorsal displacement of the distal femoral fragment.

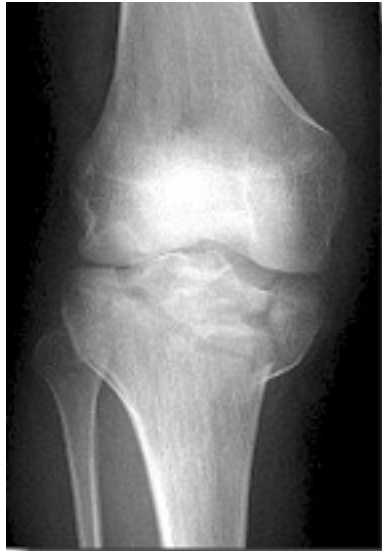

Valgus and varus are terms that are sometimes confusing. **Valgus** denotes a deformity in which the described part is angled away from the midline of the body. Conversely, **varus** (as pictured) denotes a deformity in which the angulation of the part is toward the midline.

Deviation from the normal alignment is termed **angulation**. It is important to mention the direction of angulation if it exists. This is determined by the direction of the apex of an angle formed by the two fracture fragments.

**Descriptive Modifiers:** A fracture is termed **complete** if it interrupts both cortices of the bone and **incomplete** if it involves only one. One should note whether a fracture extends into and involves an **articular surface**. Frequently, the percentage of articular surface that is involved is estimated; in some cases the percentage that is involved will dictate the need to perform a surgical reduction.

An **avulsion fracture** refers to a bone fragment that is pulled away from its normal position by either the forceful contraction of a muscle or by the resistance of a ligament to a force in the opposite direction.



**Impaction** refers to the forceful collapse of one fragment of bone into or onto another. In the proximal humerus this frequently occurs in a telescoping manner, particularly in elderly patients whose bones are soft and brittle. In the vertebral bodies, impaction frequently occurs in the form of compression. In the tibial plateau, impaction frequently occurs in the form of a depression, as pictured here.

A fracture that occurs through abnormal bone is termed pathologic. A **pathologic fracture** should be suspected whenever a fracture occurs from seemingly trivial trauma.

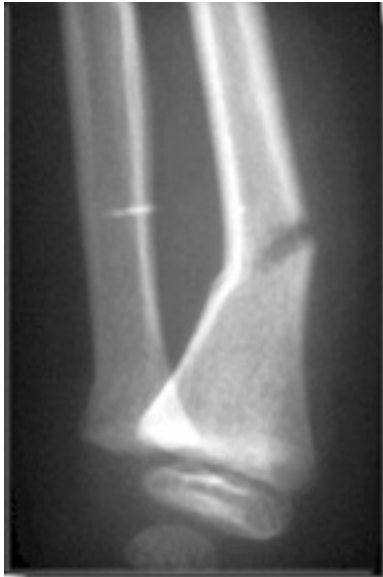Diseases that cause structural weakness predisposing to injury include metastatic carcinoma, cysts, enchondroma, and giant cell tumors.

In addition, osteomalacia, osteogenesis imperfecta, scurvy, rickets, and Paget's disease of bone may weaken bones. The term is also applied to fractures through osteoporotic bone when the demineralization is secondary to disease, as seen in polio.

Fractures through osteoporotic bone of the elderly are usually not termed pathologic. When fractures occur in normal bones with a history of "trivial trauma," one should suspect abuse or battering.

Repeated low-intensity trauma may lead to resorption of normal bone resulting in a **stress fracture**. Other names used for this condition are "fatigue fracture" and "march fracture," the latter term stemming from the tendency of this injury to occur in military recruits subjected to prolonged marching while carrying heavy gear. Most stress fractures occur in the lower extremities, and commonly afflict joggers, dancers and athletes. The metatarsals, tibia, fibula, calcaneus, femoral neck, or femoral shaft may be involved.

## Fractures in Children





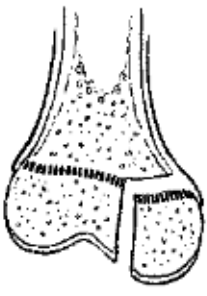
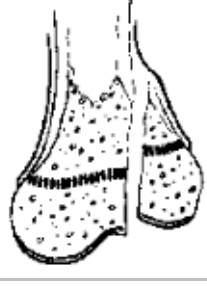
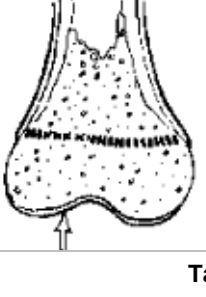
Certain features of children's bones make pediatric fractures different from those in adults. Bones of children are necessarily soft and resilient; therefore they sustain a number of incomplete fractures. **Greenstick fractures** are incomplete angulated fractures of long bones. The resultant bowing of the bone results in an appearance resembling that of a moist young branch that breaks when bent in a similar fashion

A **torus fracture** is another form of incomplete fracture, characterized by a wrinkling or buckling of the cortex (In Greek architecture, a torus is a bump at the base of a column). These may be extremely subtle on radiographs.

Another feature of growing long bones that may be a source of trouble and confusion is the presence of epiphyses: cartilaginous centers at or near the ends of bone from which growth takes place.

It is important to keep in mind that the cartilaginous portion of an epiphysis is not visualized on radiographs, as cartilage is radiolucent. There is a tendency to consider only the ossified nucleus and to ignore the cartilaginous structure that bridges to the metaphysis. It must also be remembered that cartilage is present even before an ossified nucleus is seen. A final consideration is that since a radiolucent line represents the epiphyseal growth plate, there may be confusion as to whether a fracture line is present as well. These complexities in interpreting radiographs in children dictate the occasional need to obtain x-ray views of the uninjured side for comparison.

Injuries to the epiphyses may result from either compressive or shearing forces. These injuries are relatively common during childhood, as opposed to sprains or shaft fractures, and must always be considered in children with a "sprained ankle." This is because of the relative weakness of the cartilaginous growth zone, which will separate before other stronger structures are torn or broken. Epiphyseal injuries should be described according to the Salter Harris classification.

Salter-Harris Classification	
	<p><b>Type I</b></p> <p>Fracture extends through the epiphyseal plate, resulting in displacement of the epiphysis (this may appear merely as widening of the radiolucent area representing the growth plate)</p>
	<p><b>Type II</b></p> <p>As above, in addition, a triangular segment of metaphysis is fractured</p>
	<p><b>Type III</b></p> <p>Fracture line runs from the joint surface through epiphyseal plate and epiphysis</p>
	<p><b>Type IV</b></p> <p>Fracture line also occurs as in Type III but also passes through adjacent metaphysis</p>
	<p><b>Type V</b></p> <p>This is a crush injury of the epiphysis; it may be difficult to determine by x-ray examination</p>

**Table 2 - Salter-Harris Fracture Classification**

**Type I** injuries involve only a slip of the zone of provisional calcification. Comparison radiographs are usually necessary to detect small slips. A child with swelling and tenderness over an epiphysis (for instance, of the lateral ankle) and a negative x-ray appearance, should be suspected of having had the epiphysis open, rather than having a sprain, since the epiphysis is weaker than the overlying ligaments.

**Type II** injury is similar to Type I, with an additional fracture extending into the metaphysis. (The triangular metaphyseal fragment is sometimes referred to as the Thurston-Holland sign). Type II injuries comprise approximately three quarters of all epiphyseal fractures. Since there is no germinal layer involvement, there is usually no growth disturbance with Type I and II injuries.

**Type III** injuries are comprised of a slip of the growth plate, plus a fracture through the epiphysis, involving the articular surface. Since this fracture involves the germinal layer, growth may be disrupted. Anatomic reduction will reduce but not eliminate the possibility of growth disturbance.

**Type IV** fractures are similar to Type III, with the additional involvement of a metaphyseal fracture. Again, anatomic reduction is essential and usually requires surgery. Growth disturbance occurs in a high proportion of patients.

**Type V** fractures are crush injuries of the epiphyseal plate. This type of injury usually occurs in joints that move in one plane, most commonly the knee and ankle. Since this injury occurs in a radiolucent area, the injury may be difficult to diagnose on x-ray examination but must be suspected by mechanism of injury and pain over the epiphysis. Growth arrest is the rule in this injury. Fortunately Type V injuries are rare.

## Diagnostic Modalities for Fracture Diagnosis

**Plain Roentgenography:** Plain roentgenography is the mainstay of diagnosis of fractures. In addition to confirming or ruling out fractures, other pathologic conditions can be ruled out. With penetrating trauma, foreign bodies, air, and gas may also be detected. With trivial trauma, and when good follow-up is assured, it is acceptable to delay x-ray films in the interest of cost saving. However, this delay cannot be permitted when a potentially "harmful-if-missed" injury such as a nondisplaced hip fracture may be present.

It is important that the physician be familiar with routine radiographic views as well as specialized views, (e.g., the Judet's view of the acetabulum or the sunrise view of the patella). At least two views perpendicular to each other are necessary in examining long bones. In certain locations, such as the phalanges, oblique views are always obtained. If doubt still exists, one should ask for more views in various degrees of angulation to the other films. Recall that a fracture line will be most visible when it is parallel to the x-ray beam and will be invisible when it is exactly 90 degrees to the beam. When a long bone is fractured, it is imperative that the bone be viewed radiographically in its entire length. The physician must examine each film to assure that proper technique is used and that no important area is cut off the film. Overexposed films may fail to reveal a pathologic condition that is present.

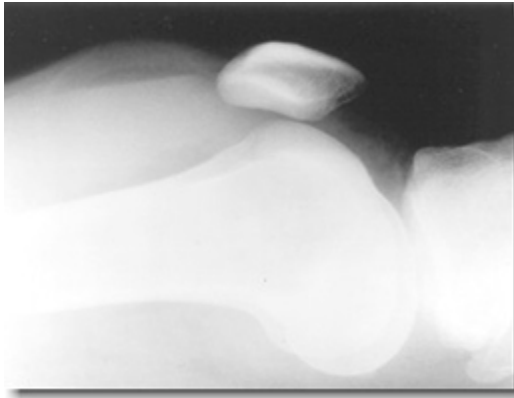
Even with good technique, some fractures are not visible initially and will not appear until the margins of the fracture absorb. Absorption will widen the radiolucent line and a defect should be present in 7 to 10 days. At that time, new bone produced beneath the periosteum at the margins of the fracture will also accentuate the fracture. From the above discussion, it should be clear that if a fracture is suspected but not visible at the initial visit, the injury should be treated as a fracture and reexamined radiographically in 7 to 10 days, and the patient should be informed of the rationale for this regimen.

Stress views of joints are used by some to evaluate the degree of ligamentous injury. Valgus or varus stresses in the ankle joint are sometimes used but generally are best left to the orthopedist. Those who argue against the use of such stress views point out that there is risk of further injuring an already

traumatized structure, that pain may prevent sufficient stress for diagnosis, and that there is additional radiation exposure for the patient and the technologist.

Comparison views are useful in selected situations but should not be routinely performed in all pediatric exams, as some have advocated. If a fracture is definitely present on the affected side, the comparison view exposes the child to radiation and adds expense with no benefit. Similarly, an experienced physician will generally be able to read a normal film with reasonable certainty. More useful for a young child is obtaining a wide field of the affected extremity, since the child will often not localize the pain well. This is especially true with regard to complaints of knee pain, cases of hip injury, or wrist complaints in forearm and elbow injury. Comparison views are sometimes helpful in adults when there is a question of accessory ossicles or nonfused bones (e.g., bipartite patella) since these anomalies are usually bilateral.

Interpretation of radiographs must be performed in a systematic manner. Mistakes will be made if a proper view box, hot light (when appropriate), and enough time are not used. Holding films up to ceiling fluorescent lights is bound to lead to problems. Soft tissues should be examined before the bones are considered.



The bleeding that inevitably accompanies fractures may produce soft tissue swelling and may impinge on or obliterate overlying muscle planes. **Fat pads**, such as in the elbow, may be displaced. Another useful sign is the fat-fluid level (**lipohemarthrosis**) that may accompany fractures which extend into the knee joint; this will only be visible, however, if cross-table technique is used.

The bones themselves should be systematically examined by following the contour of each completely. Normal adult bones possess a smooth unbroken contour. A sharp angle, for instance where the head of a bone joins its shaft, is highly suggestive of a fracture. A lucent line that interrupts the smooth contour and in the adult usually extends to the opposite side represents the usual fracture. Nutrient arteries may be confused with fractures but radiographically have different characteristics: they are fine, sharply marginated, extend obliquely through the cortex, and are less radiolucent than fractures. **Soft-tissue folds, bandages, or other overlying material can create pseudofractures.** If one traces lucencies to see whether they extend beyond the bones, this mistake can be limited. Anomalous bones may likewise be mistaken for fractures. However, avulsions and small fracture fragments will have an irregular, uncorticated surface and a defect in the adjacent bone, whereas anomalous ossification centers (accessory ossicles) and sesamoids will be characterized by smooth cortical margins. Reference texts may be useful in confirming these anomalies. Compression fractures are represented by increased density rather than a lucency.

## Special Imaging Techniques

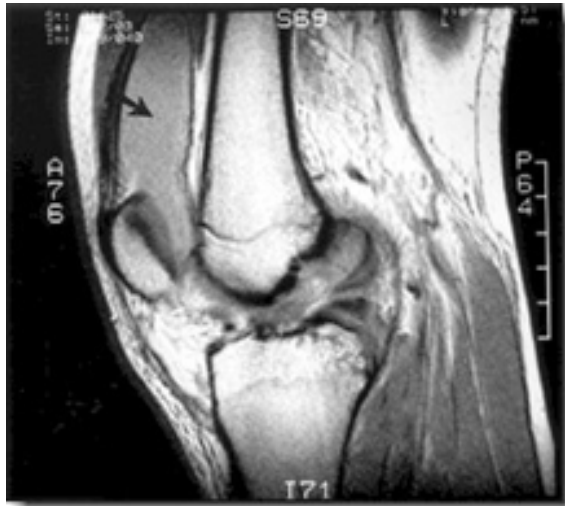**Radionuclide Bone Scanning:** Radionuclide bone scanning (also called bone scintigraphy) is used to detect skeletal abnormalities that are not evident radiographically in children and adults. Technetium polyphosphate TC 99 components are taken up where there is reactive bone formation. Occult fractures, especially stress fractures, and acute osteomyelitis can be revealed. A limitation of bone scanning is that fractures must be at least 72 hours old for the study to be sensitive. Scintigraphy is also used by some as an adjunct in the evaluation of suspected victims of child abuse.



**Computed Tomography (CT scan):** A CT scan is used to confirm suspicious fractures in some cases, or to better define displacement, alignment, or fragmentation of fractures. In the former category, thin-section coronal imaging is frequently used when facial bone fractures are suspected. CT scanning is also useful in trauma to rule out cervical spine fracture when plain films are equivocal.

Even when plain x-ray films demonstrate a fracture, CT scanning is frequently used in noncompressive vertebral fractures to assess the number of fragments and their spatial relationship to the spinal canal. A CT scan is also frequently used to define the integrity of articular surfaces, especially in the acetabulum but also in the knee, wrist, and ankle.

**Magnetic Resonance Imaging (MRI)**



The MRI is the most advanced noninvasive examination of orthopedic structures; it delineates bony lesions and also lesions of cartilage, ligaments, and other structures, such as menisci or discs. It is expensive, however, and its use should be reserved for instances when the diagnosis is in doubt and specific findings will alter the treatment. Currently, it is not possible to obtain an MRI stat from the emergency department in most settings. Other limitations include the presence of cerebrovascular aneurysm clips or pacemakers, which are contraindications to the study, and the patient must be confined in a rather small space while the examination is performed.

**Complications of Fractures**

**Hemorrhage:** Because of the rich blood supply to the skeleton, fractures may result in large amounts of blood loss, shock, and even death from exsanguination. Pelvic fracture in particular may cause great blood loss because adequate tamponade is not possible. In adults, blood loss may range from 100 ml for a forearm fracture to 3 L from a pelvis fracture (Table 29-2). Ongoing hemorrhage from a pelvis fracture may also lead to disseminated intravascular coagulation (see Chapter 85).

Fracture Site	Expected Blood Loss
Radius and ulna	150-250
Humerus	250
Tibia and fibula	500
Femur	1000
Pelvis	1500-3000

**Table 3 - Blood Loss Associated with Fractures in Adults**

**Vascular Injuries:** Vascular injuries are characteristically associated with certain fractures, and the emergency specialist who is familiar with the more common of these is forearmed in avoiding the tragedy of limb loss. High impact or rapid deceleration are the mechanisms associated with these injuries. Fractures and dislocations about the knee result from tremendous force and often injure the popliteal artery. Besides mechanism of injury, location of a fracture should suggest a vascular component. Rib

fractures may be accompanied by intercostal artery injuries that may produce significant blood loss and even exsanguination.

In the extremities, assessment of vascular injuries may or may not be straightforward. The initial survey should note the presence or absence of pulses and the state of capillary filling. If an end artery is completely disrupted, the tissue distal to the injury may exhibit pain, pallor, pulselessness, paresthesias, and paralysis. However, if collateral circulation is present, these signs may not be present even in the face of a major vascular disruption. It is worth while to not that if a limb has gotten to the point of pain, pallor, pulselessness, paresthesias, and paralysis major damage has already occurred. Likewise, in the unconscious, multiply traumatized patient, major vascular injuries may not be obvious. Therefore, mechanism of injury and anatomy must dictate the need to assess a possibly injured vessel. If pulses cannot be palpated, a Doppler stethoscope should be used to listen for blood flow. Even palpable pulses may be misleading, however, since it has been demonstrated that in 10% to 15% of significant arterial injuries, distal pulses may initially be normal. When pulses are present but the mechanism of injury suggests the possibility of vascular injury, arteriography should be performed. Late complications of undiagnosed vascular injuries include thrombosis, arteriovenous fistulas, aneurysm, false aneurysm, and tissue ischemia with limb dysfunction.

**Nerve Injuries:** Nerves can be injured by both blunt and penetrating trauma or iatrogenically. Neuropraxia is the contusion of a nerve, with disruption of the ability to transmit impulses. Paralysis, if present, is transient, and sensory loss is slight. Normal function will usually return to a neuropraxic nerve in weeks to months. Axonotmesis is a more severe crush injury to a nerve. The injury to nerve fibers occurs within their sheaths. Since the Schwann tubes remain in continuity, spontaneous healing is possible but slow. Neurotmesis is the severing of a nerve, usually requiring surgical repair. Certain nerve injuries characteristically accompany particular fractures

Orthopedic injury	Nerve injury
Elbow injury	Median (esp. with displaced supracondylar fracture) or Ulnar
Shoulder dislocation	Axillary
Sacral fracture	Cauda equina
Acetabulum fracture	Sciatic
Hip dislocation	Femoral nerve
Femoral shaft fracture	Peroneal nerve
Knee dislocation	Tibial or peroneal
Lateral tibial plateau fracture	Peroneal

**Table 4 - Orthopedic injury and commonly associated nerve injury**

When the nerve is completely severed, all functions will be absent, including superficial sensation to touch, pain and temperature; deep sensation to muscle and joint movements, position, deep pressure and vibration; motor supply and deep tendon reflexes (to distally innervated muscle groups); and response to electric stimulation. For less severe injuries any subjective change in sensation should be noted. Light touch is a good screening test. Two-point discrimination is a more sensitive examination and should be used routinely in evaluating digital nerves. Normal two-point discrimination at the fingertips is 4-6 mms. In the young child, examinations that require a subjective response may be misleading. If doubt exists about a digital nerve injury in a child, soak the digit in a basin of saline for 20 or 30 minutes. If the skin wrinkles, the digital nerve is intact, whereas absence of wrinkling indicates a nerve injury.

**Compartment Syndrome:** This serious complication should be considered whenever pain and paresthesias occur in an extremity following a fracture that occurs in a closed muscular compartment. Pain will be increased with passive stretching of the involved muscles, with active contraction against resistance, or with direct pressure on the compartment. **Compartment syndrome is a surgical emergency** with the most common site being the anterior compartment of the lower leg. Other sites of

compartment syndrome include the posterior, deep posterior and lateral compartments of the lower leg, the gluteal compartments, dorsal and volar compartments of the forearm and the interosseous compartments of the hand. A compartment syndrome that is not relieved promptly will lead to irreversible damage to muscle and nerves. Tissue ischemia begins when compartment pressures exceed 30 mm Hg. As muscle cells become necrotic, they are replaced with yellow fibrous tissue. Nerves are enveloped by a constricting thickened epineurium. Joints affected by this pathophysiology become fibrotic and contracted and eventually resist any attempt at passive motion. The end result of this ischemic process is termed Volkmann's ischemic contracture. Prevention by **early recognition** and restoration of circulation is key.

**Avascular Necrosis:** Because of their blood supply, certain bones may undergo avascular necrosis following open fracture, particularly if they are comminuted and if they go untreated for any length of time. The scaphoid, capitate, and femoral head are particularly prone to this complication due to their tenuous vascular supply.

**Reflex Dystrophy:** This posttraumatic syndrome has three clinical stages: early, dystrophic, and atrophic. Early on there is a constant aching or burning in the affected limb. Motion or external stimulation increases these bothersome symptoms, usually out of proportion to the original injury. Over the following months, during the dystrophic stage, the skin of the affected extremity becomes glossy and cold, and there is limited range of motion. Finally, skin atrophy and contracture may develop. Other names for this syndrome include Sudeck atrophy and causalgia.

**Fat Embolism:** The appearance of intravascular fat droplets occurs in nearly one out of five patients admitted with major trauma, though not all will be symptomatic or require treatment. The fat embolism syndrome most commonly follows long bone fractures in the young adult (usually tibia and fibula) and is also seen with hip fractures in the elderly. An **adult respiratory distress syndrome (ARDS)**, characterized by tachypnea, dyspnea, and pulmonary edema, is the earliest, most common, and serious manifestation. Neurologic involvement, manifested as restlessness or confusion, is also an early sign, as is a petechial rash. Fever, tachycardia, jaundice, retinal changes, and renal involvement may occur. Fat is seen in the urine in 50% of patients within 3 days of the injury.

Hypoxemia is common and needs to be monitored with blood gases. Treatment is supportive and similar to that for RDS of other origins.

## Complications of Immobilization

Fractures frequently result in long periods of immobilization; in and of itself this immobility often presents serious medical problems, especially in the elderly. These include pneumonia, deep venous thrombophlebitis, pulmonary embolism, urinary tract infection, wound infection, decubitus ulcers, muscle atrophy, stress ulcers, gastrointestinal hemorrhage, and psychiatric disorders. Thus, early ambulation is a major goal of optimal orthopedic care.

**Fracture Healing:** The goal of fracture care is to realign bony fragments so that healing or union can take place and normal function is restored. The progression from fracture to union begins with a hematoma that bridges the fragments, progresses to an inflammatory phase, and ends with remodeling. The rate of fracture healing is affected by many factors, including the type of bone (cancellous bone heals faster than cortical bone), degree of fracture and opposition, and systemic states such as hyperthyroidism or excess corticosteroids. Exercise speeds healing whereas chronic hypoxia has been known to slow repair.

Complications of Fractures	Complications of immobility
<ul style="list-style-type: none"> <li>• Hemorrhage</li> <li>• Vascular injuries</li> <li>• Nerve injuries</li> <li>• Compartment syndrome</li> <li>• Volkmann's ischemic contracture</li> <li>• Avascular necrosis</li> <li>• Reflex dystrophy</li> <li>• Fat embolism</li> </ul>	<ul style="list-style-type: none"> <li>• Pneumonia</li> <li>• Deep venous thrombophlebitis</li> <li>• Pulmonary embolism</li> <li>• Urinary tract infection</li> <li>• Wound infection</li> <li>• Decubitus ulcers</li> <li>• Muscle atrophy</li> <li>• Stress ulcers</li> <li>• Gastrointestinal bleeding</li> <li>• Psychiatric disorders</li> </ul>

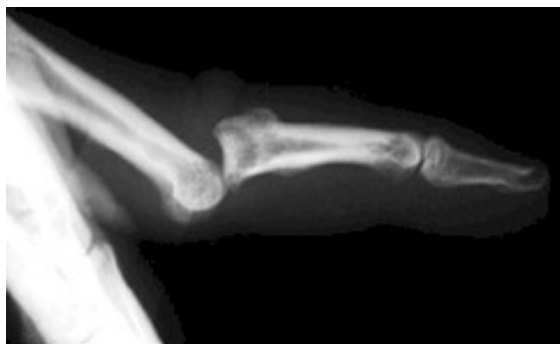**Table 5 - Complications of fractures and immobilization**

Several terms are used to denote abnormal union.

- **Delayed union** is that which takes longer than the time normally required for a particular fracture location.
- **Malunion** occurs when there is a residual deformity.
- **Nonunion** is the failure of a fracture to unite; when nonunion results in a false joint, the result is termed a pseudarthrosis.

## Subluxation and Dislocations

**Nomenclature:** Abnormal forces applied to joints may result in the loss of continuity between two opposing articular surfaces. Partial loss of continuity is termed **subluxation**, whereas complete loss is termed **dislocation**. In general, these injuries are named for the major joint involved, as in the dislocated shoulder or hip. In three-bone joints the injury is named for the joint involved if the disturbance involves the two major bones involved or, if the lesser bone is involved, the disturbance is named for that bone. Hence, separation of the femur from the tibia is termed dislocation of the knee, whereas displacement of the patella from its normal articulation is termed dislocation of the patella. At the elbow, separation of the olecranon from the humerus is a dislocation of the elbow, whereas separation of the radius from the humerus is termed radial head dislocation.



Dislocations and subluxations should be described according to the direction of the distal segment relative to the proximal segment or of the displaced bone relative to the normal structures. Thus the injury pictured here is termed dorsal dislocation of the proximal interphalangeal joint of the index finger. Disruption of articulation may also occur in combination with a fracture. The term fracture dislocation is used to describe this combination.

If the overlying skin is broken in any way, dislocations, subluxations, or fracture dislocations are described as open and constitute the same emergency, as does an open fracture.

**Assessment:** In most cases there is severe to excruciating pain because the joint capsule is stretched. Attempts at motion of the joint will intensify the pain. This useful sign is lost in the unconscious, obtunded,

or intoxicated patient and may lead to failure to diagnose if a careful survey is not performed. Some dislocations will have an obvious deformity such as the anterior shoulder dislocation, whereas others may be subtle, such as posterior shoulder dislocation (as occurs with seizure or electrocution). Swelling of soft tissues may also obscure the diagnosis, such as in the tarsal-metatarsal region. Gentle passive testing of range of motion should be performed but never forced. Assessment for neurovascular function is similar to that for fracture. Certain dislocations (e.g., knee) are so commonly associated with vascular injuries that arteriography is mandatory. Plain x-ray studies will detect dislocations provided that the correct views are ordered (see chapters on specific joints). Radiographs should be performed before and after attempts at relocation of initial or complicated dislocations.

**Treatment:** In relocating joints a few general principles apply. The sooner a joint is relocated the better. Later, swelling and muscle spasm will make reduction more difficult. Also, pain will not be adequately relieved until the dislocation is reduced. In the hip, immediate reduction is mandatory to preserve vascular supply.

Prior to attempting relocation, adequate analgesia or anesthesia should be used. Nerve blocks are especially useful on the digits. For larger joints, intravenous narcotics (which are reversible) should be used liberally; short-acting intravenous benzodiazepines are a useful adjunct with proper attention given to possible respiratory depression.

The general principle of relocation is to recreate the injury, pulling the proximal end of the dislocated bone out and away from whatever is trapping it in its final resting place. As this is accomplished, the disarticulated surface is manipulated back toward its normal anatomical position. If the reduction is problematic, it should not be forced. A single good attempt is better than repeated attempts in an inadequately relaxed patient. Some joints cannot be reduced in the emergency department because the opposing muscles (of the dislocated part) are contracting too forcefully and general anesthesia is required. In other cases mechanical obstruction by a torn piece of cartilage, tendon, or joint capsule may necessitate open reduction in the operating room.

## Soft Tissue Injuries

### Sprains

**Nomenclature:** Ligamentous injuries resulting from an abnormal motion of a joint are termed sprains. A sprain is defined as injury to the fibers of a supporting ligament of a joint. Physicians treating acute injuries should be familiar with the ligaments that are commonly sprained and should be aware of the functional implications of these injuries so that the patient can be properly informed and managed.

Sprains may be graded according to the severity of pathologic findings; clinically, however, the distinctions are often indistinct. **First-degree sprains** are characterized pathologically by minor tearing of ligamentous fibers, with resultant mild hemorrhage and swelling. Minimal point tenderness can be elicited. Stressing the ligament will produce some pain, but there is no opening or abnormal joint motion.

A **second-degree sprain** is a partial tear of a ligament; pathologically, more fibers are torn than in the first-degree injury. Clinical findings include moderate hemorrhage and swelling, tenderness, painful motion, and loss of function. There may be a tendency toward persistent instability and recurrence, especially if the sprain is treated improperly.

A **third-degree sprain** describes the complete tearing of a ligament. Signs are a further exaggeration of those mentioned for second-degree sprain. Additionally, stressing the joint will reveal abnormal joint motion, provided that this is not limited by pain or swelling. Interestingly third degree sprains will occasionally show very little tenderness. Analgesia and the evacuation of a hemarthrosis may be used to allow a more complete diagnosis of these injuries. Instability is the rule if severe ligamentous injuries do

not heal properly. Since ligaments are relatively avascular, healing is slow, and patients with significant sprains should be informed of this.

**Assessment:** The clinical presentation of a patient with a sprain of the extremity may be indistinguishable from that of the patient with a fracture. The injury will frequently occur during a vigorous athletic activity where forces are applied in opposite directions result in a joint being stressed in an abnormal or exaggerated direction. The patient will frequently complain of hearing a "snap" or a "pop" at the moment of injury and on this basis will be convinced that a fracture must be present. Patients also frequently report "seeing stars" or "almost passing out" at the moment the injury occurred and may still be in extreme pain, appearing pale and diaphoretic if seen shortly after the injury. It is appropriate to administer analgesia to such patients.

The emergency department evaluation should include a careful history of the exact sequence of events at the time of the injury, as well as the position of the extremity and the forces applied to it at the moment of injury; a history of any audible sounds at the time of injury should also be sought. Examination of the joint should then take place with the joint stressed to demonstrate abnormal motion. The proper method of stressing certain joints needs to be reviewed for each joint; in some instances local anesthesia is necessary to perform an adequate examination. Plain radiography is indicated in most cases to rule out avulsion fracture or other fractures. In children, epiphyseal fractures will occur more commonly than ligamentous disruption because of the relative ligamentous strength in comparison to the ease of epiphyseal separation. Stress radiographs are preferred by some experts (especially in the ankle) to rule out sprain. Arthroscopy (e.g., for cruciate tears) and MRI are playing increasingly important roles in the follow-up evaluation of these injuries when disability is significant.

**Treatment and Disposition:** Specific management of sprains varies, depending on the location and severity of the injury. In general, initial measures should include **ice, elevation, and analgesia**. Nonsteroidal antiinflammatory drugs (NSAIDs) seem to be effective analgesics in many patients, but their role in altering the pathophysiologic condition is unclear at this time. Immobilization and no weight bearing is the mainstay of initial management for most injuries. Since the severity of the injury is often difficult to establish at the first visit, it is better if any doubt exists to over treat (e.g., application of a plaster splint rather than an ace bandage for ankle sprains) until the extent of injury can be better determined. Protected weight bearing for lower-extremity injuries will provide patients with comfort and protect the impaired part. Epiphyseal injuries similarly require immobilization.

In the elderly, safe ambulation can sometimes not be accomplished, and a short hospitalization should be arranged. For complete or nearly complete ligamentous disruption (third-degree sprain) urgent orthopedic consultation is usually necessary. Less severe injuries can be followed up between 3 and 7 days post-injury when acute swelling has subsided. If possible, copies of x-ray films ordered in the emergency department should be sent with the patient to the orthopedist. Patients are frequently casted at that time, and they should be informed of that possibility at their initial visit. Since ligaments are relatively avascular, healing is slow, and patients with significant sprains should be informed of this as well.

Sprains should be diagnosed as precisely as possible and should not be trivialized. Too often, after radiographs have ruled out fracture of an affected extremity, the term sprain is applied rather indiscriminately, or the patient is told that the injury is "only a sprain." The expression "only a sprain" is misleading and should not be used by health professionals.

## **Strains**

**Nomenclature:** A strain is an injury to a musculotendinous unit resulting from violent contraction or excessive forcible stretch; the term pulled muscle is sometimes used interchangeably with muscle strain. The injury is graded in a manner similar to that of a sprain.

**A first-degree strain** is a minor tearing of the musculotendinous unit, characterized by spasm, swelling, local tenderness, and minor loss of function. Findings increase along a continuum such that in a **second-degree strain** more fibers are torn but without complete disruption; swelling, ecchymosis, muscle spasm, and loss of strength are more marked. In a **third-degree strain** the muscle or tendon is completely disrupted, with resultant separation of muscle from muscle, muscle from tendon, or tendon from bone. An avulsion fracture may be present on radiographs.

**Assessment:** Signs and symptoms include marked pain and spasm, ecchymosis, swelling, and loss of function. A force applied to the muscle will produce sharp pain at the site of injury; a palpable defect is frequently present at the site of rupture as well. Sometimes a bunching up of the muscle may be appreciated, as is typically seen in a biceps muscle rupture.

In the non-athlete, strains usually present in patients that have over-stressed a muscle group or who have tried to generate excessive force in a cold or non-conditioned muscle. Examples are the weekend gardener or mover who presents on Monday morning with lower back strain, the aerobics student who strains the rectus muscle, and the novice weight lifter who presents with chest wall pain secondary to pectoral strain. These are usually first-degree injuries, and the onset is slow. Rapid acceleration in a tennis player, for instance, may result in a third-degree gastrocnemius tear, just as pushing off to jump often ruptures the Achilles tendon in the basketball player. Not infrequently the sudden violent attempt at lifting in the older individual results in a complete biceps disruption. Sudden generation of the tremendous forces of which the thighs are capable frequently results in second-degree strain of the thigh adductors, hamstrings, or quadriceps muscles.

In the athlete, generation of tremendous contraction forces coupled with excessive forcible stretching (while the body may be either accelerating or "planting") results in severe strains. Involvement of almost any muscle group is possible, and the onset of such injuries is usually acute. Immediate removal from activity, application of ice, and rest are mandatory to prevent further injury.

**Treatment and Disposition:** Treatment will depend on the degree of disruption, the location, and the functional loss. Most first-degree injuries will respond in a few days to rest, application of ice, elevation, analgesics, and NSAIDS. Second-degree strains are treated similarly, with immobilization of the affected part required for longer periods. Passive stretching during the early days post-injury will impede healing and may result in fibrosis or calcium deposition in injured muscle. For patients with significant lower back injuries and in competitive athletes, a physical therapist may help in the rehabilitation process. Third-degree strains are treated similarly in the emergency department, along with early orthopedic consultation. Some of these injuries are amenable to surgical repair whereas others may be treated with immobilization. The muscle affected, the age of the patient, occupation, and activity level are all factors in deciding on whether surgical intervention is appropriate.

Proper training, warm-up and stretching exercises, and avoidance of overexertion can accomplish prevention of many strains. Emergency personnel themselves should seek to avoid these injuries in the course of their demanding work, especially during patient transfers.

### **Tendonitis**

Tendinitis is an inflammatory condition characterized by pain at tendinous insertions into bone; it is frequently the result of overuse. Common sites are the rotator cuff of the shoulder, the Achilles tendon, the radial aspect of the wrist (de Quervain's tenosynovitis), and the insertion of the hand extensors on the lateral humeral epicondyle (tennis elbow). In some locations, particularly the shoulder, chronic irritation results in calcium deposition along the course of the tendon; when present, the painful condition that ensues is termed calcific tendinitis.

Physical examination typically presents with pain on motion and limitation of function. Point tenderness and palpable crepitus over the involved tendon with motion is generally present. In general, a clinical test can be performed by forcible flexion of the involved muscle while keeping the point of insertion fixed, or by operating the involved muscle against resistance. Either test should intensify the discomfort. Radiographs are usually negative. A small fleck of bone may suggest an avulsion, or the surface of the bone at the attachment may be roughened, indicating periostitis. As mentioned, there may also be calcium deposits along the course of the tendon.

Treatment of tendinitis consists of rest, ice, and NSAIDs. Peritendinous local infiltrations of anesthetics and corticosteroids are also useful but should not be repeated too often because tendon rupture may occur. Injection therapy is especially useful in calcific tendinitis around the shoulder. Injection of the Achilles tendon is not advised because of reports of rupture from even a single injection.

## **Bursitis**

Bursitis is a painful inflammation of the bursa that may be either traumatic or infectious. Commonly involved sites include the olecranon, the greater trochanter of the femur, and the prepatellar and anserine bursae around the knee. Physical findings are tenderness and swelling over the involved bursa, whereas warmth and erythema may signal infection. If infection is suspected, aspiration with Gram's stain and culture of the bursal fluid are mandatory. Otherwise, treatment may be conservative and is similar to that for tendinitis.

## **Management Principles**

### **Emergency Splinting and Dressing**

Fractures or dislocations that are suspected or proven should be splinted to avoid damage to muscles, nerves, vessels, and the skin. Splinting may also restore blood flow to ischemic tissue by removing pressure caused by a bone fragment resting against a blood vessel. Finally, splinting relieves pain; conversely, movement of fracture fragments results in severe pain.

Pre-hospital Approach Splinting should begin in the pre-hospital phase of care. There are numerous commercially available devices, and most ambulances carry some of these. Minimal equipment will include long and short backboards, cervical collar and sandbags, and extremity splints. A half-ring traction splint is also essential. Inflatable air splints are favored by some because they are convenient, easy to apply, transparent, and radiolucent and they tamponade low-pressure bleeding. These devices should be inflated only by mouth and to the point that still permits indentation by gentle finger pressure.

When commercial splints are not available, many everyday items can be substituted. Once such splints are applied, it is unnecessary to change to a fancier device when the patient arrives at the emergency department if the material used was correctly applied and allows penetration by x-rays.

Field personnel are taught to "splint 'em where they lie," which means that suspected fractures should be splinted before the patient is moved. Severely angulated long bone fractures should be straightened in the pre-hospital setting before they are splinted. Splints should be applied in such a way as to immobilize the joints above and below the fracture site to avoid motion of the involved bone. The skin should be padded to avoid local necrosis, and the splint should be secure by a circumferential wrapping material. This material should allow for some expansion and should not be applied in a constricting manner.

Suspected cervical spine injuries should be immobilized by foam blocks or similar objects placed on either side of the head to prevent motion. In addition, the forehead should be secured by use of strap, adhesive tape, or a gauze bandage, which is then attached to the board or bed on which the patient is lying. It cannot be overemphasized that all unconscious patients should have their necks immobilized in



some manner until radiographs have ruled out cervical spine fracture. Patients with possible thoracic or lumbar vertebral injuries should be placed on a backboard and moved only by "logrolling" until fracture has been ruled out.

## Emergency Department Approach

Once patients are brought to the emergency department, the indications for splinting are the same as in the field. All splints should be checked and, if properly applied, need not be changed. Sometimes, more effective devices such as Buck's traction are applied in the emergency department. Splints are a means for offering external stability, thus "temporary" splints may be applied to reduce patient discomfort while diagnostic testing is being obtained. Remember that a properly applied splinting device will relieve pain from a fracture rather than exacerbate it.

Splinting or other immobilization is also used after diagnosis and treatment of injuries. In some cases splints are all that is needed for definitive treatment, whereas at other times these devices are temporizing while emergency department personnel are addressing more life-threatening conditions, waiting for the diagnostic studies, swelling to diminish or until orthopedic consultation is available.

Injuries other than sprains and fractures also benefit from immobilization; these include inflammatory and infectious processes, bites, burns, and repaired injuries of muscle bellies or tendons. Splints can also be used to improve function, such as with wrist drop that accompanies radial nerve palsy. Once the injury is immobilized, it is important to stress elevation of the affected part to avoid edema formation.

### Spine

When a spinal injury is suspected, immediate immobilization is mandatory. In the early phases of management, the cervical spine can be immobilized with foam blocks and firm collar along with adhesive tape across the forehead. In restless or intoxicated patients efforts to restrain the patient should include attention to the maintenance of cervical spine protection. A thoraco-lumbar injury can be immobilized by keeping the patient supine on a firm backboard.

Immobilization of the patient supine on a backboard with the head taped down is uncomfortable to the patient at best and fraught with danger at worst. Such patients should not be left unattended, and every effort should be made to get them out of this position, if warranted, as soon as possible.

### Upper Extremity

#### Shoulder immobilizer

This appliance is useful in immobilizing the shoulder, humerus, and elbow and is used after reduction of dislocated shoulders and to treat impacted fractures of the humeral neck. Care should be taken to pad and powder the axilla to avoid skin maceration.

#### Clavicle Splint

A factory-made, figure-of-eight clavicle strap is available, or one can be fashioned from tubular stockinette. The factory model is easy to apply and less likely to stretch. It should be adjusted firmly but not so tightly as to compress the axillary artery or brachial plexus. The axillae should be padded and powdered to avoid skin maceration. The therapeutic value of the clavicular splint is unclear.

#### Plaster Splints

Well-fitting noncommercial plaster splints can be fashioned from plaster and may be used to immobilize the elbow, forearm, wrist, or hand. First, the injured part should be wrapped with Webril or other padding.

Plaster should never be applied directly to the skin. Then six to eight layers of plaster strips are placed inside a piece of stockinette, immersed in water, and applied to the affected part. While the plaster is still wet, an elastic bandage is wrapped over it and the splint is molded to the desired position as the plaster hardens.

### **Forearm and wrist splints**

Numerous preformed splints are available for splinting fractures of the distal forearm and wrist. These offer the advantages of being lightweight, neat, and easy to apply, and are also easily removed and replaced by the patient.

### **Pelvis**

The pneumatic antishock garment (MAST trousers) should be applied in the pre-hospital setting to any patient suspected of having an unstable pelvic fracture. The MAST trousers limit bleeding by compressing and immobilizing the fracture, reducing further blood loss. In the emergency department, if a patient with known or suspected pelvis fracture has been transported without MAST trousers, consideration should be given to applying the device if the patient requires fluid resuscitation or while the patient is being moved, e.g., for radiographic procedures.

### **Lower Extremity**

#### **Hip and Femur**

Fractures of the hip and femoral shaft can be immobilized by using a traction device such as the Hair traction splint or a similar appliance. These devices should be applied in the pre-hospital setting if possible. The principle is that a proximal pad engages the ischial tuberosity for countertraction while the longitudinal traction is applied through the ankle by means of an ankle hitch. A commercial ankle hitch is recommended, but if one is not available. Shoes serve as protection from the pressure of straps and should not be removed. The patient's ankle, Achilles tendon, and arch of the foot should be padded, and the circulation should be checked to make sure it is intact.

The Sager splint is a newer device that seems to offer advantages over previous appliances in that it is applied to the medial and lateral aspect of the thigh. This makes it more acceptable for use in the presence of pelvic fractures and avoids compression to the sciatic nerve. Also, the amount of traction is metered at the ankle and over-traction can be avoided.

#### **Knee**

Knee corsets or immobilizers are commercially available devices that can be used after acute injuries. Frequently these are used after trauma to let the knee "cool off" and allow better physical examination in a few days. Short and long models are available.

#### **Ankle**

Immobilization of the ankle can be accomplished by a number of means. Plaster splints can be used temporarily for the treatment of nondisplaced ankle fractures or for the treatment of severe sprains. An alternative method is to apply a full circular cast, bivalve it on either side, discard the anterior piece, and affix the posterior mold with an elastic bandage. Most ankle injuries should be splinted with the patient's ankle in neutral position. Injuries to the Achilles tendon, plantaris muscle, or gastrocnemius muscle are best treated with the foot held in equinus. The toes should be free to move distal to the metatarsophalangeal joints, and the proximal border should end below the tibial tubercle to avoid putting pressure on the peroneal nerve.

An additional option for minor ankle sprains is a commercial ankle support with Velcro straps (e.g., Air Cast). This product may be worn in the patient's shoe and permits early weight bearing.

## Casts

Plaster casts perform a similar function, as do splints in that they provide stability and relieve pain. More securely than a splint they also immobilize injured parts in a position that will enhance healing.

Casts are not mandatory for all fractures, and in situations where they are, application is usually not an immediate necessity. For these reasons and because of the many problems associated with casts, many emergency physicians choose not to apply circumferential casts themselves. A discussion of the techniques for casting is therefore omitted from this text. If one wants to become proficient in casting it is best to be taught by a skilled practitioner and to practice rather than learn from a textbook.

Patients who have had plaster casts put on by other physicians may present to the emergency department for complaints related to their casts. These will usually be pain, local irritation, swelling, or numbness of the distal part. A cast that is too tight will result in swelling, pain, coolness, and change in skin color of the distal parts. Pain may also be due to the initial injury or due to local pressure, or it may be secondary to a developing compartment syndrome or wound infection. The safest thing to do if a patient complains of pain is to bivalve the cast and inspect the extremity. This is done by cutting the plaster and the padding on each side and removing half the cast at a time, using the other half as a mold to keep the extremity immobile. Afterward, the bivalved cast can be held together with bias-cut stockinette or elastic wrap until a new cast is applied. If relieving external pressure does not alleviate symptoms, the diagnosis of compartment syndrome needs to be seriously considered.

Casts may obscure wound infections, sources of sepsis, and even tetanus. One should not hesitate to bivalve the cast and inspect the extremity when dealing with a serious medical problem.

## Analgesia and Anesthesia

One of the principal traditional roles of the physician is to relieve (or at least diminish) pain and suffering, yet it has been shown that doctors fail to treat pain adequately. There can be little reason to withhold adequate analgesia for isolated orthopedic injuries. Aside from their use as therapeutic agents, many of the modalities listed below should also be considered in order to perform an adequate exam, especially in ligamentous injuries.

**Narcotics:** Narcotics, naturally occurring opium alkaloids or semisynthetic derivatives of this group, are the mainstay of analgesic therapy in the emergency department. They are the most effective agents available when given in an appropriate dose by an appropriate route. The basic principle in dosing these drugs is that they should be titrated in small increments to point of effect or side effect, whichever comes first.

- **Morphine** is the standard of this class to which all other derivatives are compared for potency and effect.
- **Meperidine** is also commonly used, whereas hydromorphone and fentanyl are occasionally given.

Whichever is chosen, the intravenous route is the safest and most effective route for providing adequate analgesia. Hydroxyzine is frequently given along with a narcotic to relieve opiate-induced nausea.

**Hydroxyzine must be given by the intramuscular route.**

**Benzodiazepines:** Many practitioners prefer a benzodiazepine in addition to or in place of narcotics for the reduction of major dislocations. These drugs possess significant sedative, anxiolytic, and amnestic properties that make them useful for this purpose. They are not true skeletal muscle relaxants, but they do effectively relieve muscle spasm. Midazolam is particularly useful because of its rapid onset of action and short half-life. One must be prepared to provide ventilatory support when this drug is used, especially in combination with a narcotic.

**Local and Regional Anesthesia:** Nerve blocks with lidocaine or a related drug can be useful in reducing a number of fractures and dislocations, especially of the wrists, hands, and feet. Recently it has been shown that addition of sodium bicarbonate to lidocaine (1 ml sodium bicarbonate, 1 mEq/ml per 10 ml 1% lidocaine added immediately before injection) can greatly reduce the pain associated with the injection.

**Nitrous Oxide:** Nitrous oxide, inhaled as a 50:50 mixture with oxygen has the advantages of safety, rapid onset and recovery time, and ease of administration. It is particularly well suited for field use during extrication or splinting. Nitrous oxide may be adjunctive to some of the previous drugs mentioned. Its proper use in children is safe and effective.

**Muscle Relaxants:** Muscle spasm may occur as an isolated phenomenon associated with strains or may accompany ligamentous injuries, overuse injuries, radiculopathy, or nervous tension. A number of drugs—including orphenadrine citrate (Norflex®), methocarbamol (Robaxin®), diazepam (Valium®), carisoprodol (Soma®), and cyclobenzaprine hydrochloride (Flexeril®)—have been promoted as skeletal muscle relaxants. The first three mentioned above are available in parenteral and oral forms. All of these produce drowsiness, and it is likely that most of their benefit is achieved by sedation and forced rest.

**Nonsteroidal Antiinflammatory Drugs (NSAIDs):** These drugs are not only useful for treating inflammatory conditions (bursitis, tendinitis) or the inflammation associated with other injuries, but also for their analgesic properties. Some studies claim the analgesic effect of NSAIDs to be comparable to that of oral narcotics for specific syndromes, but without addiction or abuse potential. Parenterally administered NSAIDs offer great opportunity for acute pain relief without oversedation. The incidence of gastrointestinal, hepatic, renal, and hypersensitivity complications is not insignificant and needs to be monitored.

The response to the various NSAIDs varies with any individual and among individuals, and the failure of one does not negate the value of others. Aspirin is the cheapest and oldest member of this group, and its use as an agent of first choice should be strongly considered. NSAIDs are absolutely contraindicated in those who are taking warfarin preparations, those who have a history of ITP or who have a history of hypersensitivity to these agents.

**Pediatric Analgesia and Anesthesia:** Fear of adverse side effects, unfamiliarity with dosages and the widespread belief that children do not experience pain as much as adults leads to the underuse of analgesics in children. Narcotics, benzodiazepines, nitrous oxide, and local anesthesia all have their place in treating children. Some advocate the use of ketamine as well. The ideal regimen remains to be defined.

## Common Pitfalls

Orthopedic injuries are quite dramatic and tend to distract an examiner from other, potentially life-threatening, injuries. Remember to do your ABCs and address orthopedic injuries during your resuscitation.

Always assess neurovascular status distal to the injury during the initial assessment and after application of a splint. These items are frequently omitted from documentation.

A common issue in fracture care is that "the most commonly missed fracture is the second one." Be sure to look for a second fracture after finding one fracture on a radiograph.

Epiphyseal development at several major joints, showing age at which these secondary ossification centers appear in on x-rays and age, in parentheses, at which union occurs.

Many anatomic variants may be mistaken for fractures on radiographs. Knowledge of the most common of these will prevent many misdiagnoses. Additionally, clinical correlation should be sought, and comparison radiographs of the other side may be helpful. The excellent text by Keats may also be consulted.

## References

1. Green NE: Vascular injury associated with dislocation of the knee. *J Bone Joint Surg.* 1977;59(2):236.
2. Geiderman JM: Orthopedic Injuries: Management Principles. In Rosen P, Barkin R (eds): *Emergency Medicine Concepts in Clinical Practice.* St. Louis: C.V. Mosby, 1992.
3. Kinzl L, Burri C, Coldeway J: Fractures of the pelvis and associated infra-pelvic injuries. *Injury* 1982;14:63.
4. Evers BM, Cryer HW, Miller FB: Pelvic fracture hemorrhage. *Arch Surg* 1989;124:422.
5. Mucha P, Welch TJ: Hemorrhage in major pelvic fractures. *Surg Clin North Am* 1988;68:757
6. Brown JJ, Green FL, McMillen RD: Vascular injuries associated with pelvic fractures. *Am Surg* 1984;50:150.
7. Siverhus SW, Amis JA: A practical guide to acute compartment syndrome. *J Musculoskeletal Med* 1988;88-103.
8. Strauss MB, Hargens AR, Gershun DH, et al: Delayed use of hyperbaric oxygen for treatment of a model anterior compartment syndrome. *J Orthopedic Res* 1986;4:108-111
9. Benke PI: Jessica in the well: Ischemia and reperfusion injury. *JAMA* 1988;259(9):1326.

## Suggested Reading

1. Burgess AR, Tiel M: Fractures of the pelvis. *Fractures in Adults.* Philadelphia: J.B. Lippincott, 1991.
2. Chapman MW: Open fractures. *Fractures in Adults.* Philadelphia: J.B. Lippincott, 1991.
3. Damron T, McBeath A: Diagnosis and management of vascular injuries associated with skeletal trauma. *Orthop Rev* 1990; 19(12): 1063-1070.
4. Esterhai JL Jr: Management of soft tissue wounds associated with open fractures. *Instructional Course Lectures* 1990;39:483-486.
5. Gustilo RB, Merkow RL, Templeman D: The management of open fractures. *J Bone Joint Surg* 1990;72(2):299-304.
6. Harkess JW, Ramsey WC: Principles of fractures and dislocations. *Fractures in Adults.* Philadelphia: J.B. Lippincott, 1991.
7. Heckman JD: Fractures. Emergency care and complications. *Clinical Symposia* 1991;43(3):2-32.
8. Karavias D, Korovessis P, Filos KS, et al: Major vascular lesions associated with orthopedic injuries. *J Orthop Trauma* 1992; 6(2):180-185.
9. McAndrew MP, Lantz BA: Initial care of massively traumatized lower extremities. *Clin Orthop* 1989;243:20-29.
10. Moore MN: Orthopedic pitfalls in emergency medicine. *South Med J* 1988;81(3):371-378.
11. Patzakis MI, Wilkins J: Factors influencing infection rate in open fracture wounds. *Clin Orthop* 1989;243:26-40.
12. Schlickewei W, Kuner EH, Mullaji AB, et al: Upper and lower limb fractures with concomitant arterial injury. *J Bone Joint Surg* 1992;74(2):181-188.
13. Selingson D, Henry SL: Treatment of Compound fractures. *Am J Surg* 1991;161(6):693-701.
14. Sunderland S: The anatomy and physiology of nerve injury. *Muscle Nerve* 1990;13(9):771-784.
15. Wilkins J, Patzakis M: Choice and duration of antibiotics in open fractures. *Orthop Clin North Am* 1991;22(3):433-437.